

Leukemic Anaplasias Reflecting Physiologic Cytogenesis of Myeloid System

M. R. Parwaresch, H. K. Müller-Hermelink and K. Lennert

Department of clinical and general pathology
University of Kiel

Cytological abnormalities in granulocytes occurring in myeloproliferative diseases prove sometime to be highly revealing in connection with cytogenetical considerations. A good body of techniques have been applied in tracing the developmental line of blood cells. In table 1, a survey of the widely applied methods for the demonstration of the derivation of the granulocytes from their marrow precursors is presented.

Table 1: Survey of methods devised for cytogenetic studies on hemopoetic cells

1. GENERAL MORPHOLOGY
Size, Form, Granules
2. MORPHOLOGY OF NUCLEI
Size, Form, Density, Segmentation
3. ULTRASTRUCTURE
4. FUNCTIONAL ACTIVITY
Phagocytosis, Granule discharge
5. CYTOCHEMICAL PROPERTIES
Chemical markers
6. DIRECT OBSERVATION
Derivation in mono-cultures
7. CELL-TRANSFER IN SYNGENEIC ANIMALS
Radio-labelled
Enzyme polymorphism
8. MARKER-CHROMOSOMES
9. OBSERVATIONS IN LEUKEMIAS

Revealing informations have been gained on the bases of cytochemical studies. Of special significance proved hydrolytic enzymes as well as dyes with a special affinity to certain cellular structures. These reactions could appropriately be used for the identification of different granulocytic strains. In this context they represent "chemical markers".

Being aware of the differences in the significance of each of these techniques we are going to depict their applicability to the problems of the granulocyte derivation. For the selective visualization of the different granulocytic cell-line the

following four techniques have been applied. These methods fulfil the prerequisites indispensable for cytogenetical considerations: reproducibility, specificity to special cell strain and constancy of the reaction pattern.

1. The naphthol AS-D chloroacetate esterase reaction performed as described by MOLONEY (1960) and LEDER (1964) to visualize promyelocytic azurophil granules and the neutrophilic cell-line (Fig. 1).

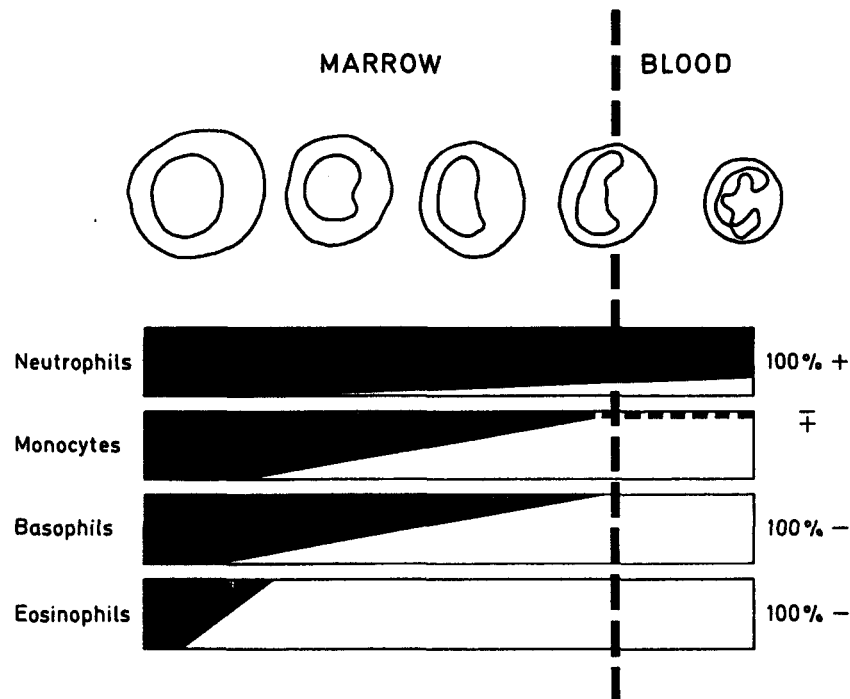


Fig. 1: Naphthol AS-D chloroacetate esterases activity in normal granulopoietic cells from promyelocytes to mature granulocytes.

2. α -naphthylacetate esterase as given by WACHSTEIN and WOLFF (1958) for the staining of blood monocytes (LÖFFLER 1961).
3. Toluidin blue stain for the demonstration of the metachromasia in basophil cell-line following proper fixation of their water soluble granules (PARWARESCH and LENNERT 1967).
4. Para - dimethylaminobenzaldehydnitrite (ADAMS 1957) reaction for the selective visualization of eosinophil cell-line (LEDER et al. 1970; LEDER and PAPE 1971). In this reaction structures rich in tryptophane as extracellular fibrin precipitations and RUSSEL bodies reveal also a positive reaction. The separation of these structures however presents no significant difficulties.

Under non neoplastic conditions significant variations in the reaction pattern do not occur. By combination of these methods it is possible to trace back the derivation course of the monocytes (LEDER 1967); basophils (PARWARESCH et al. 1971) and eosinophils (LEDER and PAPE 1971) from the promyelocytes. Promyelocytes, as schematically demonstrated in Fig. 2, gradually develop specific properties of monocytes (activity to α -naphthylacetate esterase reaction) or that of basophils (toluidin blue metachromasia) or that of eosinophils (positive ADAMS reaction). In the same time a progressive reduction of the chloroacetate esterase activity occurs as the specific secondary granules develop. All transitional forms

presenting both, properties of promyelocytes and those of individual granulocytes, can easily be detected (fig. 2).

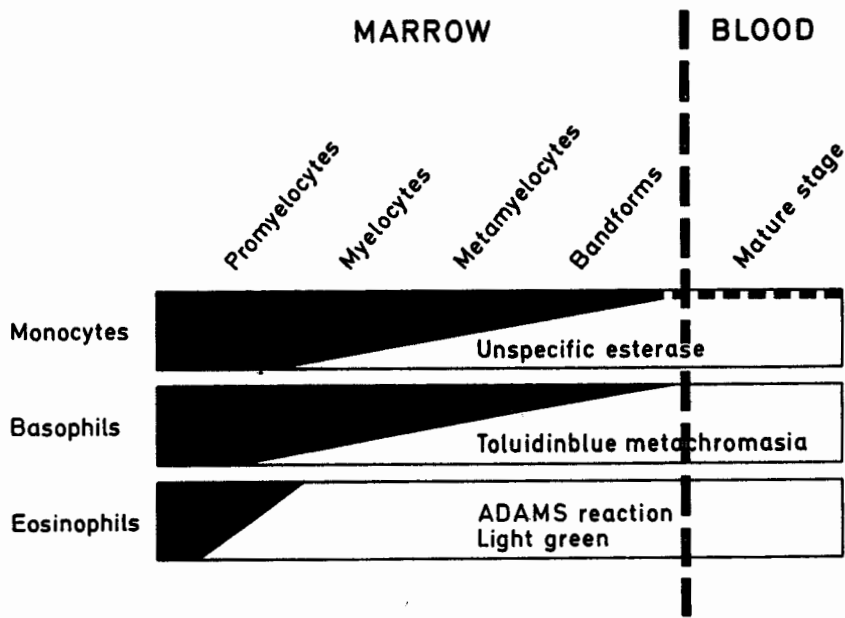


Fig. 2: Demonstration of the granulocyte maturation as observed by the combined application of LEDER's esterase with α -naphthylacetate esterase reaction (monocytic cell-line), with toluidin (basophil cell-line) and with light green or ADAMS reaction (eosinophil celline). For further explanation refer to text.

In fig. 3 the reactivity of the individual granulocytes to the four applied methods is demonstrated. In case of naphthol AS-D chloroacetate esterase reaction neutrophils reveal an invariable strong activity. A minor number of monocytes present a fine granular weak reaction. Basophils and eosinophils are invariably






Reactivity to:	Neutrophils	Monocytes	Basophils	Eosinophils
Naphthol AS-D Chloroacetate E.R.				
α -Naphthyl Acetate E.R.				
Toluidinblue Metachromasia				
ADAMS R.				

Fig. 3: Reactivity of mature granulocytes and monocytes to the four cytochemical techniques applied.

negative. Monocytes are the only leukocytes presenting a significant activity to α -naphthylacetatesterase reaction. Toluidin blue metachromasia is strictly confined to basophils. The same is valid for eosinophils respecting ADAMS reaction.

In case of myeloproliferative diseases a variety of divergences from the normal reaction pattern have been demonstrated (UNDRITZ 1963; LEDER 1972; PARWARESCH 1975). These deviations have been regarded as neoplastic abnormalities.

There have been reports on basophils (PARWARESCH 1975) and eosinophils positive to chloroacetatesterase reaction (LÖFFLER 1969; LEDER 1970) in cases of myeloproliferative diseases. Irrespective of the presence of this property in the marrow precursors of basophils and eosinophils, themselves lacking this property as normal mature granulocytes, it were impossible to understand the mechanism and the significance of such an occurrence in neoplastic variants. Apparently normal populations of basophils or eosinophils positive to chloroacetatesterase reaction in myeloproliferative diseases reflect the farreaching disturbance of the control mechanisms of the maturation process. This abnormality seen with eosinophils and basophils is strictly confined to myeloproliferative diseases. In fifteen cases of excessive reactive leukocytoses including some leukemoid reactions no single basophil or eosinophil positive to chloroacetatesterase could be detected. It further underscores the existence of a single promyelocyte as the common precursors of at least these two granulocyte types and neutrophils. The latter is the only one of the three granulocytes, which retains the azurophil promyelocytic granules up to the mature stage.

A further observation in myeloproliferative diseases is the occurrence of granulocytes in bone marrow and peripheral blood which possess specific eosinophil as well as basophil granules. They are positive to chloroacetatesterase and to ADAMS reaction as well as to toluidin blue metachromasia. Coinciding of different properties, specific to individual granulocytes in the same cell is a further and a highly suggestive argument in favour of a common precursor for the three granulocyte types. Recent investigations have maintained further proof for this mode of granulocyte derivation. It could be well established, that monocellular cultures of single promyelocytes give rise to neutrophil granulocytes and monocytes. A fact which has been long expected on the basis of the frequency of myelomonocytic leukemias (LEDER 1970).

Summary

Naphthol AS-D chloroacetatesterase activity in peripheral blood granulocytes is confined to neutrophils which are all positive and to a minor part of monocytes. Its occurrence in eosinophils and basophils indicate a myeloproliferative disease. This chemical property can reliably be applied to separate neoplastic from reactive forms of quantitative and qualitative leukocyte alterations. The developmental line of this specific myeloid cellular attribute has been presented to elucidate its diagnostic significance and its validity as proof for existence of a common promyelocyte from which neutrophils, monocytes, basophils and eosinophils originate.

References

- Adams, C. W. M.: A p-dimethylaminobenzaldehydnitrite method for the histochemical demonstration of tryptophane and related compounds. *J. clin. Path.*: 10, 56–62 (1957).
- Leder, L.-D.: Der Nachweis von Naphthol AS-D Chloracetat Esterase und seine Bedeutung für die histologische Diagnostik. *Verh. dtsh. Ges. Path.*: 48, 317–320 (1964).
- Leder, L.-D.: Die fermentcytochemische Erkennung normaler und neoplastischer Erythropoiesezellen in Schnitt und Ausstrich. *Blut*: 15, 289–293 (1967).
- Leder, L.-D.: Akute myelo-monocytäre Leukämie mit atypischen Naphthol AS-D Chloracetat Esterase-positiven Eosinophilen. *Acta haemat. (Basel)*: 44, 52–62 (1970).
- Leder, L.-D., H. J. Stutte und B. Pape: Zur selektiven Darstellung von eosinophilen Granulozyten und ihren Vorstufen in Ausstrichen und Schnitten. *Klin. Wschr.*: 48, 191–192 (1970).
- Leder, L.-D. and B. Pape: Cytological and cytochemical investigations on the origin of human eosinophilic granulocytes. *Beitr. Path.*: 143, 241–248 (1971).
- Leder, L.-D.: Histochemie und Cytochemie der Leukosen. In: *Leukämie*. Ed.: R. Gross u. J. van de Loo, Springer Verlag Berlin–Heidelberg–New York (1972).
- Löffler, H.: Cytochemischer Nachweis von unspezifischer Esterase in Ausstrichen. *Klin. Wschr.*: 39, 1220–1227 (1961).
- Löffler, H.: Cytochemische Klassifizierung der akuten Leukosen. In: *Chemo- und Immuntherapie der Leukosen und malignen Lymphome* (Stacher, A., Hrsg.) Wien: Bohmann-Verlag (1969).
- Moloney, W. C., K. McPherson and L. Fliegelman: Esterase activity in leukocytes demonstrated by the use of naphthol AS-D chloroacetate substrate. *J. Histochem. Cytochem.*: 8, 200–207 (1960).
- Parwaresch, M. R. und K. Lennert: Löslichkeit und Fixierungsmöglichkeiten der Blutbasophilen-Granula des Menschen. *Z. Zellforsch.*: 83, 279–287 (1967).
- Parwaresch, M. R., L.-D. Leder and K. E. G. Dannenberg: On the origin of human basophilic granulocytes. *Acta haemat.*: 45, 273–279 (1971).
- Parwaresch, M. R.: Pathologie, Histochemie und Elektronenmikroskopie der basophilen Leukämie. 3. internationale Arbeitstagung über Proliferative Erkrankungen des myeloischen Systems. Wien, 19.–22. März (1975).
- Undritz, E.: Die Peroxydasereaktion und ihre praktische Bedeutung. In: *Cyto- und Histochemie in der Hämatologie*. S. 193–216. 9. Freiburger Symposium (Merker, H. Hrsg.). Berlin–Göttingen–Heidelberg Springer Verlag (1963).
- Wachstein, M., and G. Wolf: The histochemical demonstration of esterase activity in human blood and bone marrow smears. *J. Histochem. Cytochem.*: 6, 457 (1958).